

Gynekologicko – pôrodnické oddelenie
Nemocnica A. Wintera
Piešťany

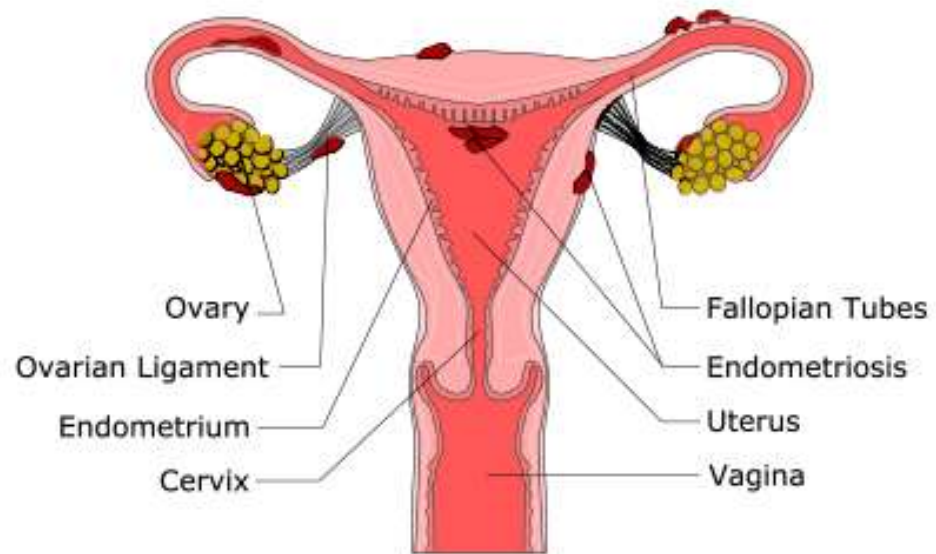
Endometrióza

Benígne ochorenie s malígnymi príznakmi

MUDr. Nikola Kapičák Lukáčová

Definícia

ENDOMETRIOSIS



História

John A. Sampson

- ▶ prvý použil termín endometrióza -1927
- ▶ popísal čokoládové cysty na vaječníkoch
- ▶ teória retrográdnej menštruácie

Karol Rokitanský

- ▶ novotvary na vaječníkoch- sarkómy
- ▶ cystosarcoma adenoides uterinum



Epidemiológia

7-10% žien

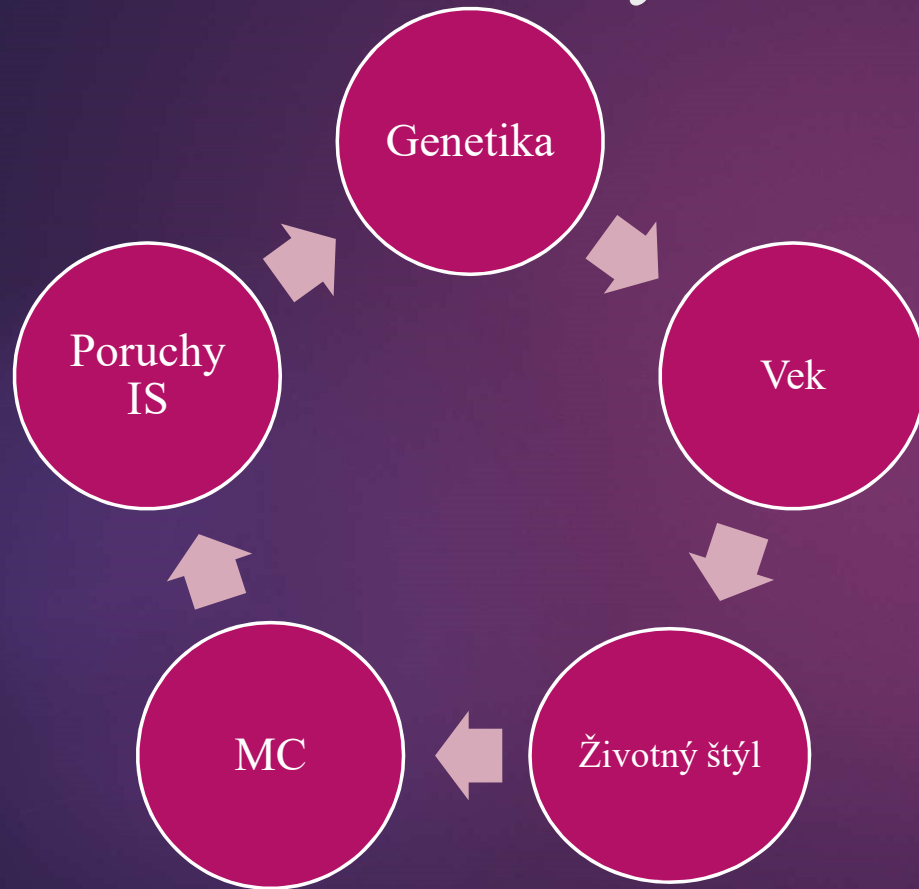
Dg.
panvovej
bolesti v
80 %

Neplodné
ženy 20-
50%

Bez
príznakov
20-50 %



Rizikové faktory



HYPOTÉZY VZNIKU

- RETROGRÁDNA MENŠTRUÁCIA
- MEYEROVA METAPLASTICKÁ
- HALBANOVA VASKULÁRNA
- INDUKČNÁ
- GENETICKÁ
- IATROGÉNNA
- TEÓRIA KMEŇOVÝCH BUNIEK







Klasifikácia

1. Klasifikácia americkej spoločnosti pre reprodukčnú medicínu

2. Skóre ENZIAN




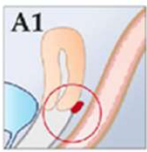

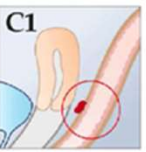
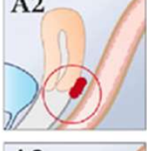
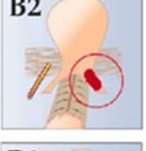

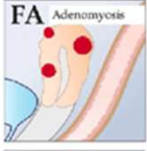


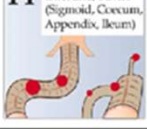
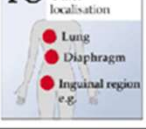
3. Index plodnosti a endometriózy

4. Klasifikácia Americkej asociácie gynekologických laparoskopistov

STAGE I (MINIMAL)	STAGE II (MILD)	STAGE III (MODERATE)
		
<p>PERITONEUM Superficial endo - 1-3cm -2</p> <p>R OVARY Superficial endo - < 1cm -1 Filmy adhesions - < 1/3 -1 TOTAL POINTS 4</p>	<p>PERITONEUM Deep endo - > 3cm -6</p> <p>R OVARY Superficial endo - < 1cm -1 Filmy adhesions - < 1/3 -1</p> <p>L OVARY Superficial endo - < 1cm -1 TOTAL POINTS 9</p>	<p>PERITONEUM Deep endo - > 3cm -6</p> <p>CULDESAC Partial obliteration -4</p> <p>L OVARY Deep endo - 1-3cm -16 TOTAL POINTS 26</p>
STAGE III (MODERATE)	STAGE IV (SEVERE)	STAGE IV (SEVERE)
		
<p>PERITONEUM Superficial endo - > 3cm -4</p> <p>R TUBE Filmy adhesions - < 1/3 -1</p> <p>R OVARY Filmy adhesions - < 1/3 -1</p> <p>L TUBE Dense adhesions - < 1/3 -16*</p> <p>L OVARY Deep endo - < 1cm -4 Dense adhesions - < 1/3 -4 TOTAL POINTS 30</p>	<p>PERITONEUM superficial endo - > 3cm -4</p> <p>L OVARY Deep endo - 1-3cm -32** Dense adhesions - < 1/3 -8**</p> <p>L TUBE Dense adhesions - < 1/3 -8** TOTAL POINTS 52</p> <p>*Point assignment changed to 16 **Point assignment doubled</p>	<p>PERITONEUM Deep endo - > 3cm -6</p> <p>CULDESAC Complete obliteration -40</p> <p>R OVARY Deep endo - 1-3cm -16 Dense adhesions - < 1/3 -4</p> <p>LTUBE Dense adhesions - > 2/3 -16</p> <p>L OVARY Deep endo - 1-3cm -16 Dense adhesions - > 2/3 -16 TOTAL POINTS 114</p>

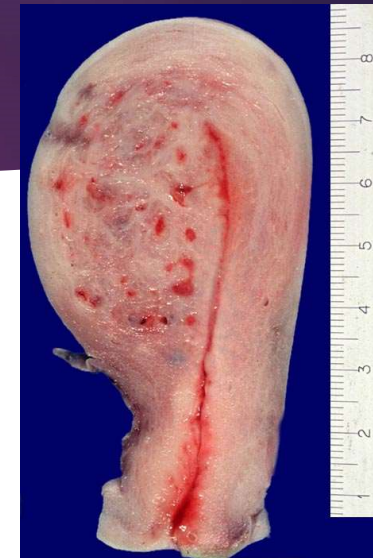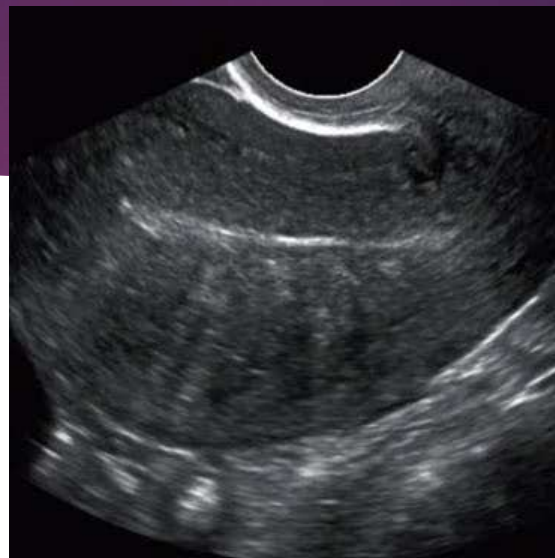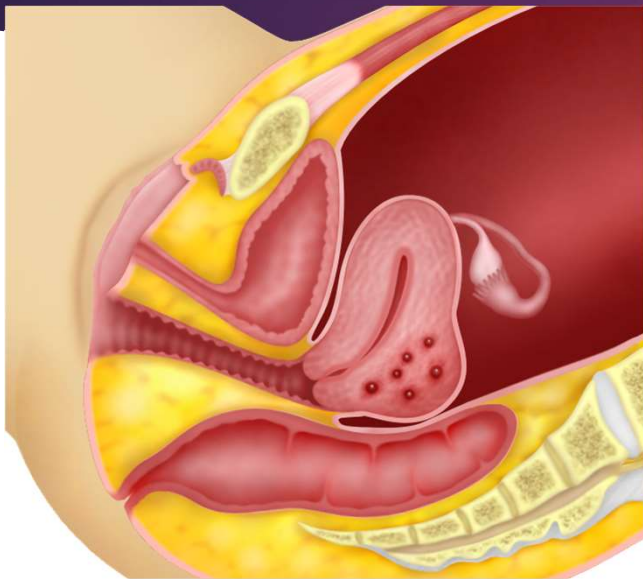
ENZIAN 2012

Classification of Deep Infiltrating Endometriosis (according to the Endometriosis Research Foundation, SEF)

Compartment A, B or C	A	B	C
Level			
1 < 1 cm			
2 1 - 3 cm			
3 > 3 cm			
F Uterine and other extragenital deep infiltration endometriosis			
			

© Keckstein

Adenomyóza



Znaky v zobrazovacích metódach

Zväčšená guľovitá maternica

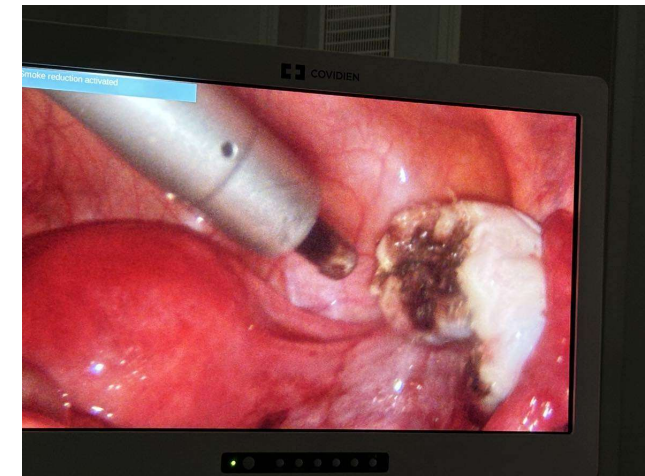
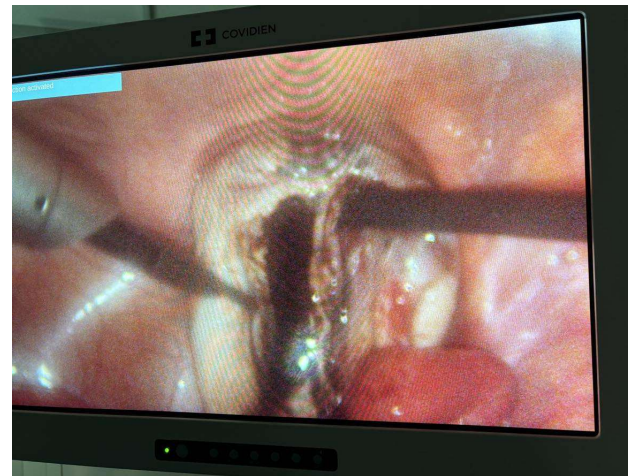
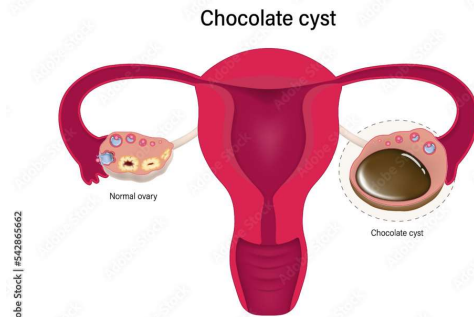
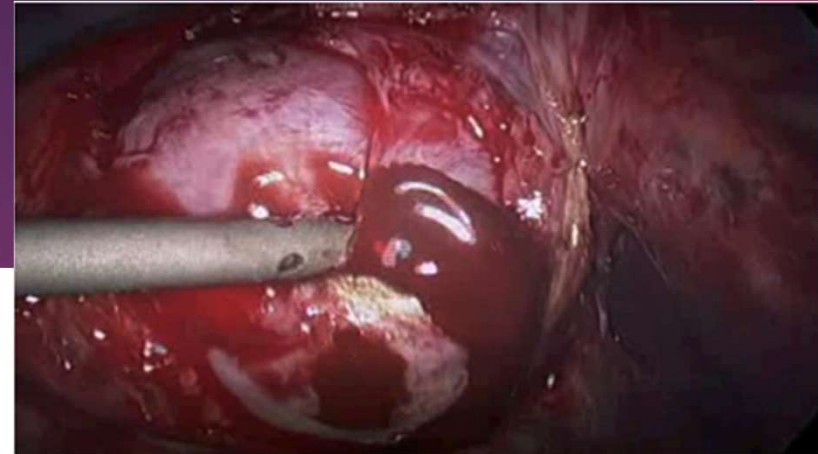
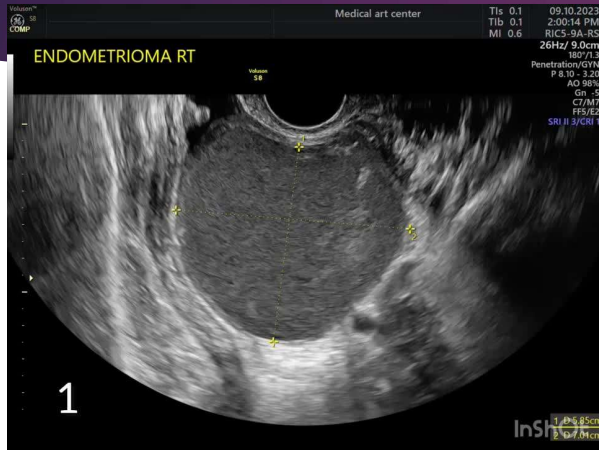
Asymetricky zosilnená zadná stena

An/hypoechogénne cysty

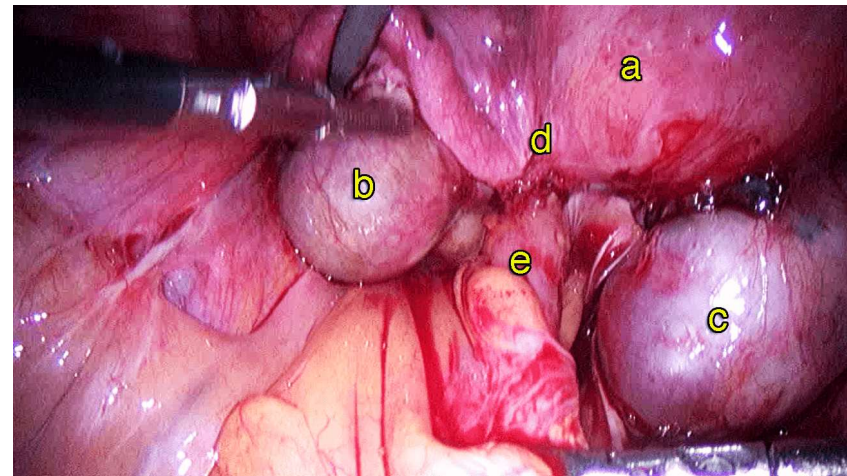
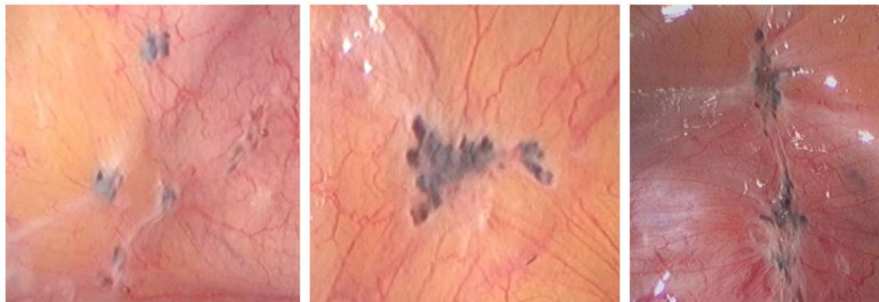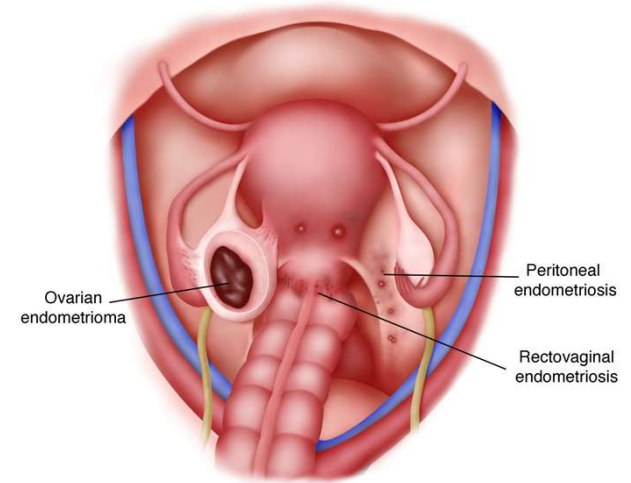
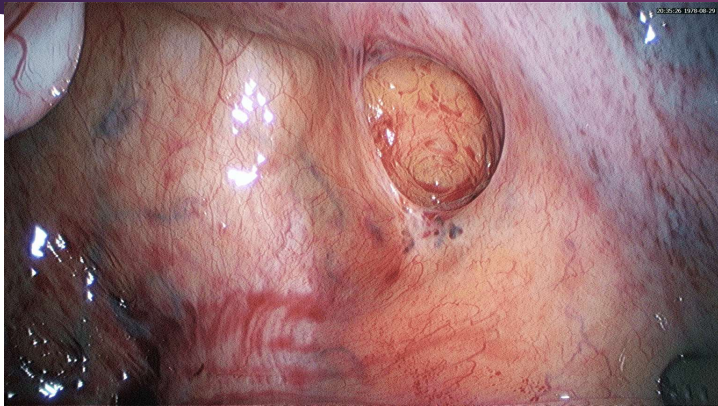
Zvýšené prekrvenie

	USG	MR
senzitivita	65 %	75,5 %
špecificita	97,5 %	92,5 %

Endometrióza ovárií



Hlboká endometrióza



Klinický obraz



Bolešť

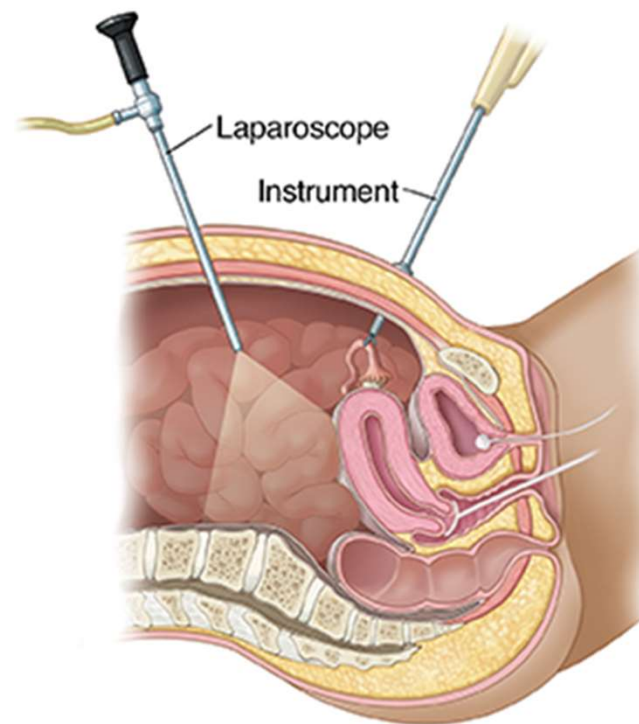
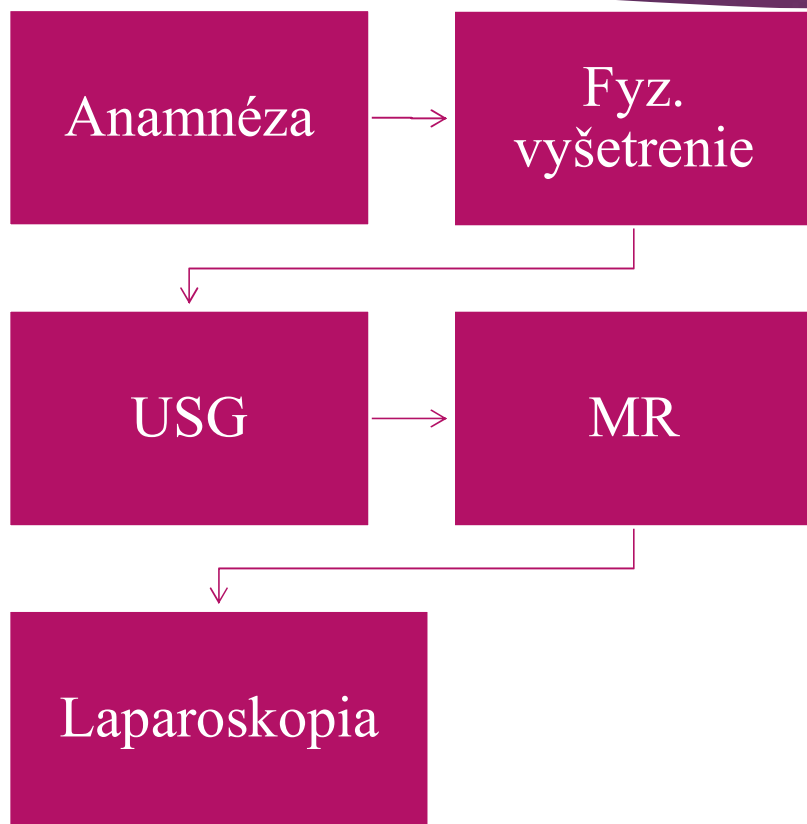
- Mierna
- Trvalá
- Cyklická
- Chronická
- Dysúria
- Bolestivé vyprázdňovanie



Neploďnosť

- 20-50% žien
- Ovplyvňovanie implantácie embrya
- Zmeny v panve
- Endokrinné poruchy
- Zmena peritoneál.f.
- Zmena funkcie endometria

Diagnostika



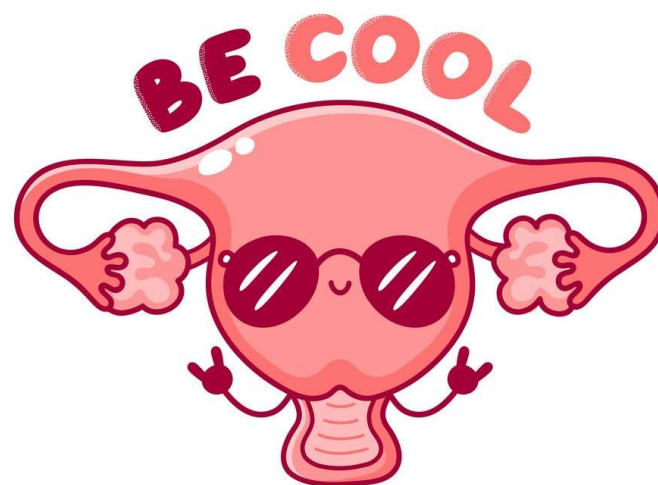Medikamentózna

- Nesteroidné antiflogistiká
- Kombinovaná HAK
- Gestagény
- Androgény
- GnRH agonisti

Chirurgická liečba

- Laparoskopický/ laparotomický prístup- zlatý štandard
- Zachovaním anatomických pomerov
- Benefit & riziko
- Peritoneálna endometrióza-do 2 mm vhodné na deštrukciu
- Ovariálna endometrióza-do 3 cm neoperujeme
- Resekcia- rektocervikálna ob., zadná klenba pošvy, rektovaginálne septum, črevná lokalizácia

Ďakujem za pozornosť



Zdroje

- ▶ HRUŠKOVÁ, H. (2011): Endometrióza: výrazný dopad na kvalitu života ženy (online). Dostupné na internete: <https://www.solen.cz/pdfs/int/2011/10/07.pdf>
- ▶ KUČERA, E.: Endometrióza. Praha: Books Print s.r.o. 2008. ISBN 978-80-7345-144-8
- ▶ GIUDICE, C., L., KAO, C., L. (2004): Endometriosis (online). Dostupné na internete: <https://pubmed.ncbi.nlm.nih.gov/15541453/>
- ▶ SANYAJ, K. AGARWAL, MD. (2019): Clinical diagnosis of endometriosis: a call to action (online). Dostupné na internete: [https://www.ajog.org/article/S0002-9378\(19\)30002-X/fulltext](https://www.ajog.org/article/S0002-9378(19)30002-X/fulltext)
- ▶ KUČEROVÁ, I.: Endometrióza v ultrazvukovém obraze. Praha: LEVRET s.r.o. 2012. ISBN 978-80-87070-64-2
- ▶ PARASAR, P., OZCAN, P., TERRY, L., K. (2017): Endometriosis: Epidemiology, Diagnosis and Clinical Management (online). Dostupné na internete: <https://www.ncbi.nlm.nih.gov/pmc/articles/PMC5737931/>
- ▶ ESKENAZI, B., WARNER, L., M. (2005): Epidemiology of endometriosis (online). Dostupné na internete: <https://www.sciencedirect.com/science/article/abs/pii/S0889854505703028>